

The use of OCT for detecting glaucoma

Optical coherence tomography (OCT) is increasingly used to aid glaucoma diagnosis. The retinal nerve fibre layer (RNFL) is the most commonly assessed structure, however measurements of the macula (e.g. ganglion cell and inner plexiform layer (GCIPL)) and optic nerve head (e.g. Bruch's-membrane opening-minimum rim width (BMO-MRW)) have also been proposed for glaucoma assessment. The aim of this article is to provide a brief update on the use of OCT as a tool to assist glaucoma detection.

Classification

OCT has a role in aiding glaucoma diagnosis, however which patients will benefit most and the optimal position of imaging in the patient pathway is still not clear. Case-control studies indicate OCT has good ability to detect glaucoma (Table 1)¹⁻⁹, with a recent Cochrane review identifying 63 studies involving a total of almost 10,000 participants.¹⁰ However, many of these studies included patients with moderate to advanced glaucoma, in whom OCT may offer little additional value for diagnosis compared to history, examination and perimetry. Several studies have shown OCT to also perform well at identifying early glaucoma (Table 1), however these studies used strict inclusion criteria, excluded poor quality scans and did not examine the performance of the normative databases often relied on to classify eyes as normal, borderline or abnormal.

Table 1. Case-control studies examining the ability of OCT to differentiate healthy and glaucomatous eyes. AUC = area under the receiver operating characteristic curve. GCC = ganglion cell complex thickness (GCIPL + macular RNFL thickness).

Study	Number of Eyes	Mean deviation (dB)	Device	Parameter	AUC
Leung et al 2009	83 Glaucoma 97 Healthy	-10.36 -0.79	Cirrus	RNFL thickness	0.962
Leung et al 2010	79 Glaucoma 76 Healthy	-10.36 -0.79	Spectralis	RNFL thickness	0.978
Mwanza et al 2011	73 Glaucoma 146 Healthy	-10.4	Cirrus	Rim area RNFL thickness	0.96 0.95
Mwanza et al 2012	58 Glaucoma 99 Healthy	-3.2 0.08	Cirrus	Rim area RNFL thickness GCIPL thickness	0.91 0.94 0.94
Sung et al 2012	144 Glaucoma 109 Healthy	-2.54 -0.45	Cirrus	Rim area RNFL thickness	0.831 0.943
Takayama et al 2012	38 Glaucoma 48 Healthy	-2.33 -0.07	Cirrus	RNFL thickness GCIPL thickness	0.89 0.82
Lisboa et al 2013	48 Glaucoma 94 Healthy	-0.81 0.02	RTVue	Rim area RNFL thickness GCC thickness	0.72 0.89 0.79
Jeoung et al 2014	164 Glaucoma 119 Healthy	-2.68 -0.22	Cirrus	Rim area RNFL thickness GCIPL thickness	0.86 0.90 0.82
Begum et al 2014	21 Glaucoma 53 Healthy	-1.9 -2.0	Cirrus	Rim area RNFL thickness GCIPL thickness	0.85 0.79 0.59

Overall, the Cochrane review found average RNFL thickness to achieve a sensitivity of 0.69 (0.63 to 0.73) for a specificity of 0.94 (0.93 to 0.95).¹⁰ Therefore, to achieve a false positive rate of 6%, using average RNFL thickness alone would miss an unacceptably high 31%

of patients with glaucoma. The authors concluded that further studies were needed to determine the value of OCT at defined stages of the clinical pathway.

A recent health technology assessment study has gone some way to addressing this by evaluating the ability of OCT to classify patients referred from community optometrists to the hospital eye service.¹¹ Using Spectralis OCT (Heidelberg Engineering), a global RNFL thickness classification of "outside normal limits" achieved a sensitivity of 0.77 (0.69 to 0.83) for specificity of 0.79 (0.75 to 0.81).¹¹ Therefore, relying on the global RNFL classification alone would miss approximately 20% of people with glaucoma and result in a 20% false positive rate. Although OCT performed better at detecting advanced glaucoma, it still missed 5% of cases.

Together these studies illustrate the importance of not relying solely on OCT classification software for detection of glaucoma. OCT should be used to supplement clinical examination and the results of visual field assessment. This is particularly important as some patients have changes detectable on automated perimetry before structural changes to the optic nerve head and RNFL are apparent.

Artefacts and limitations of OCT

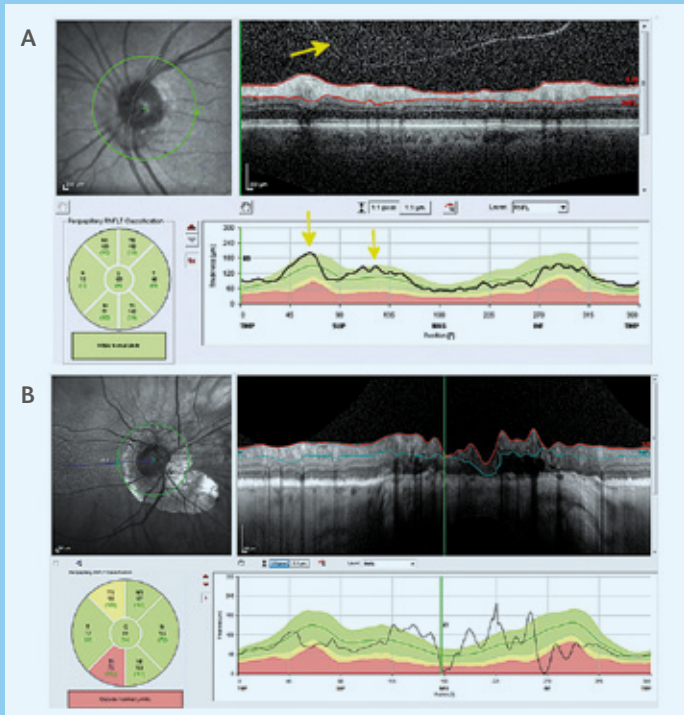
A limitation of OCT is that it struggles to classify the same eyes that clinicians have difficulty classifying. For example, patients with unusual optic discs due to high myopia, tilted optic discs, or peripapillary atrophy, in whom optic disc assessment can be challenging. Some of these patients would have been excluded from case-control studies due to their inclusion criteria. OCT is also affected by artefact. A recent review of Spectralis OCT RNFL scans (software version 4.0) from 2,313 eyes reported 46% to have at least one artefact.¹¹ The top 10 causes of artefact are shown in Table 2.

Table 2. Top 10 causes of OCT image artefact on RNFL scans.

1. De-centration (28% of scans)
2. Error associated with posterior vitreous detachment (14%)
3. Posterior RNFL misidentification (8%)
4. Poor signal (5%)
5. Anterior RNFL misidentification (3%)
6. Missing parts (2%)
7. Peripapillary atrophy associated error (1%)
8. Incomplete segmentation (1%)
9. Motion artefact (<1%)
10. Cut-edge (<1%)

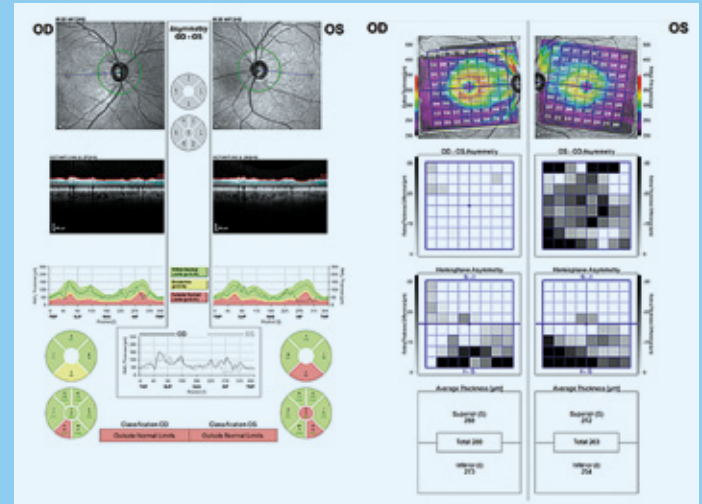
In this study, de-centration was defined as occurring when the centre of the optic nerve head was more than 10% off the centre of the circle scan. Posterior vitreous detachment (PVD) associated artefact was identified when there was a clear PVD visible on the OCT scan (Figure 1A). Vitreoretinal traction may result in erroneously thickened RNFL or there may be failure of the OCT segmentation software at the vitreoretinal interface. Poor signal was defined as a quality score <15dB. An example of peripapillary atrophy associated error is shown in Figure 1B.

Figure 1. Examples of two common causes of OCT artefact. (A) Thickening of RNFL associated with posterior vitreous detachment (arrows) and (B) segmentation error associated with peripapillary atrophy.



ability to differentiate healthy and glaucomatous subjects.¹³ A cut-off of 4.2µm asymmetry between eyes had an 82.5% sensitivity for 95% specificity. However, 70% of patients included in this study had visual field loss in only one eye, which may have heightened performance.

Figure 2. Example of posterior pole asymmetry analysis (PPAA) using Spectralis OCT (Heidelberg Engineering).



Bruch's membrane opening

Another recent development has been the realisation of the need to acquire measurements using a consistent reference landmark. In the past measurements have been taken relative to the optic disc margin, however the disc margin lacks a sound anatomical basis, and does not correspond to any defined structure on OCT, making it somewhat subjective. Using OCT radial scans, it is possible to identify the terminations of Bruch's membrane and the area enclosed, or Bruch's membrane opening (BMO).¹⁴ By centring the RNFL circle scan on the BMO rather than the disc margin, the incidence of de-centration artefact could be reduced and the repeatability of RNFL measurements improved. Also, other measurements of the optic nerve head can be obtained relative to the BMO, such as the BMO-MRW and BMO-minimum rim area (BMO-MRA). The BMO-MRW, which is defined as the shortest distance from the BMO to the internal limiting membrane, has been shown to be a good differentiator of healthy and glaucomatous eyes¹⁴, and may perform better than RNFL measurements in myopic eyes; however, it is influenced by disc size, being thinner in those with larger optic discs. BMO-MRA may overcome this limitation.

A further advantage of identifying the BMO is that it allows the scan to be aligned along an axis from the centre of the BMO to the fovea. This allows scans to be consistently aligned for progression analysis, and ensures that when the scan is compared to the normative database, corresponding clock-hours are compared reducing the chance of "red and green disease".

Summary

In summary, OCT is a valuable tool, providing a means to obtain objective measurements of the optic nerve, macula and RNFL, which when used appropriately can aid glaucoma diagnosis. An increasing number of parameters are available, which may be particularly useful in eyes with unusual optic disc characteristics, however using multiple parameters has the potential to increase false positives. It is important to exercise caution when comparing measurements to normative databases, which may not reflect the characteristics of the patient being tested. Due to high incidence of artefact, it is also essential to always review the whole scan for alignment and segmentation errors. In cases of suspected glaucoma, it may be useful to take baseline structural measurements and observe for change over time, and as some patients have changes to their visual field detectable before changes are noted on structural tests, perimetry remains essential.

Andrew Tatham, Editor, Focus

References can be accessed via the online copy of College News in the members' area of the website

Artefact can lead to "red disease" – the false assumption of glaucoma due to an OCT scan being falsely classified as outside normal limits, or "green disease" – the false assumption that a patient is normal, due to normal OCT classification in the presence of glaucoma. Incorrect classification may also occur in the absence of artefact due to the limitations of the normative databases, which tend to include mainly Caucasian patients and exclude eyes with moderate to high refractive error.

It is also important to appreciate that OCT may not reveal disc haemorrhages, an important indicator of increased risk of progression. Nevertheless, despite these limitations, OCT provides an objective, reproducible method of quantifying glaucomatous structural changes.

The macula

Recent studies have suggested macular imaging might aid glaucoma detection. The macula, which contains 50% of retinal ganglion cells, is more often affected in early glaucoma than previously thought. The macula also has less variable anatomy than the optic nerve head and is less affected by factors such as disc size, tilt, parapapillary atrophy and blood vessels, which can affect RNFL measurements. Several macular parameters can be measured including total macular thickness or GCIPL thickness. The 2015 Cochrane review examining the ability of OCT to detect glaucoma also evaluated macular measurements and found average macular parameters to have a sensitivity of 0.63 (0.57 to 0.70) for a specificity of 0.93 (0.91 to 0.94), which was remarkably similar to average RNFL thickness.¹ However, several case control studies have shown macular measurements to perform less well than RNFL at detecting early disease (Table 1).^{7,8,9,10}

It is also possible to compare macular thickness in one eye of a patient to their fellow eye using the posterior pole asymmetry analysis (PPAA) (Heidelberg Engineering) (Figure 2). Although primary open angle glaucoma is typically a bilateral disease, asymmetry is common, particularly in the early stages. Measurements such as RNFL thickness exhibit wide overlap between healthy subjects and those with early glaucoma and are influenced by factors including age, gender and ethnicity, increasing the chances of patients with different characteristics to those included in the normative database being misclassified. As many of these factors are intrinsic to the individual and will not influence asymmetry, a patient's fellow eye could serve as a useful comparative reference for the index eye. The PPAA-protocol acquires measurements from the central 20 degrees of the posterior pole and compares them to the fellow eye. It also compares superior and inferior hemifields of the same eye. In a study of 100 eyes, including 50 with early perimetric glaucoma and 50 healthy controls, PPAA asymmetry had excellent